

Experience with the new generation Micro Polyurethane covered Silicone breast implants

*Alexis Verpaele, MD
Patrick Tonnard, MD*

Introduction

After having being trained exclusively with inflatable implants, placed in a retropectoral position through a periareolar approach, it was a big step to move to a “controversial” implant as the MicroPolyurethane Surface (“MPS”) prostheses that we are using now. We have been started using MPS breast implants in 1999, early after the Polytech Silimed company introduced the implant in Belgium. Obviously we had the same negative “gut feeling” about PU which was installed among plastic surgeons for years, so a comprehensive literature search preceded the first clinical application in our population. But, as Napoleon Bonaparte said : very often “history is a collection of lies that everyone agrees about”. Indeed the “Polyurethane issue” about carcinogenicity appears to be the consequence of the gigantic overinterpretation of one animal study by Cardy in 1979 conducted on mice, reporting cancers induced by feeding them very high doses of a polyurethane degradation product.

Perhaps not very well known is that polyurethane is being used in many other medical products, such as foil cover for wounds, polyurethane gel as hydroactive wound dressing, drainage systems, but also „parenteral“ usage such as in infusion and catheter systems, as a biocompatible coating of non-inert materials, e.g.pacemakers, and as tissue friendly centre between titanium intervertebral disc prostheses.

History of MPS implants

The production of MicroPolyurethane-foam-Surfaced implants started in the late 1960's. Hal Markham bought the patent on MicroPolyurethane-foam-Surfaced implants from Pangman. Produced by Heyer-Schulte, the implant was promoted as Markham M. Prosthesis.

It only became well known since Natural Y Specialties took over the distribution and Franklin Ashley published his experience with this type of implant. As with the Cronin implant before, the MPS implant was known as the „Ashley-implant“ and later under the brand name Natural Y Prosthesis.

Ashley already described the very natural appearance of the MPS implants due to the ingrowth of the collagen fibers into the foam.

Result of the microencapsulation of the foam was a reduced capsular contracture rate, but also the natural movement of the implant with the breast tissue and prevention of dislocation.

Since manufacturing of the implants was taken over by Aesthetech at the beginning of the 1980's, the product range was extended with new shapes and profiles. To distinguish these new shapes the implants were named individually like Vogue, Optimam, Meme or Replicon.

In 1986 Aesthetech, the manufacturing unit, and Natural Y, the marketing and sales unit, were taken over by Cooper Surgical.

Major improvements were the use of highly cross-linked silicone gel with memory capabilities in the Meme and Replicon implants, something that is promoted as a recent invention, but was in fact, already known to Aesthetech at that time. The technical knowledge was taken over by the later successors and was continuously improved.

The Cooper companies were taken over by Bristol Myers Squibb and integrated into their plastic surgery unit Surgitek.

At that time, in Germany, the Surgitek Micro Polyurethane implants were distributed by Polytech GmbH, a young implant manufacturer.

In 1994 Polytech GmbH was changed into Polytech Silimed Europe GmbH.

Some of the former Surgitek designs were taken over into the new Polytech Silimed printing materials. Product names were partly taken over, like Meme or Vogue, others were changed according to changes in design, like Opticon.

Until the late 1980s in the USA MPS implants were quite popular, with a market share of up to 40%. With the change of the legal situation in the US 1991/1992 and the general discussion about silicone gel, also a discussion about MicroPolyurethane implants started. As a consequence Bristol Myers Squibb closed Surgitek and withdrew voluntarily all implants from the market, including MPS implants.

Nowadays MPS implants are only produced by the Silimed company from Brazil, and by the Polytech company in Germany.

Carcinogenicity of polyurethane : facts and fiction

The study that raised the issue of carcinogenicity of polyurethane-covered implants dates from the study by Cardy in 1979, reporting tumors, both benign and malignant, following exposure of the Fisher 344 rat to orally administered 2,4 toluediamine (2,4 TDA), a breakdown product of polyurethane. Primary hepatoma was one of the many malignancies reported. The concern was raised as a consequence of studies reporting alarmingly high levels of 2,4 TDA in both serum and urine of patients carrying MPS-covered breast implants. These studies however were flawed by the use of non-physiologic strong acid hydrolysis to prepare urine and serum samples for analysis creating artificially elevated 2,4 TDA levels. At the request of the FDA a study was carried by Hester et al to determine whether women would be exposed to 2,4 TDA as a consequence of the biodegradation of PU. This study revealed no detectable 2,4 TDA levels in the serum of either patients with MPS implants or in controls. The levels of 2,4 TDA measured in the urine of 30 out of 61 patients with MPS implants represent a theoretical lifetime cancer risk of 1.1 in one million, assuming that animal data are relevant to humans. Indeed, epidemiological studies of workers at polyurethane manufacturing sites exposed to high 2,4 TDA levels have shown no increased risk for cancer of any type. In 1995, the FDA released a report confirming that *“it is unlikely that even one of the estimated 110.000 women with PU-covered implants will get cancer as a result of exposure to TDA”*.

Misunderstandings about biodegradation and complete disappearance of the MPS foam could be clarified with scans of the encapsulated foam under an electronic microscope. Even after 9 years the structure of the foam is still very present.

Women with and without implants were examined for TDA release. From their examinations, Hester and colleagues could confirm the previous FDA stated additional cancer risk from a pair of breast implants with 1:1 million. Scientifically this is not significant and does not stand in any relation to the benefit for the patient.

Advantages and Limitations - Clinical

There is ample data available to support the statement that MPS-covered implants give a better protection against capsular contracture than any other implant. With this knowledge in mind, for us the greatest advantage of these implants is to be able to insert a mammary prosthesis resting assured

that we are performing a safe procedure, even on the long run. Of the 1184 implants we have placed, so far only one has presented with a segmental capsular contracture over Baker class 1 (see section “Complications”).

A correction of capsular contracture around another implant is an absolute indication for using an MPS implant. Take into account that a complete capsulectomy or a site change from pre to retro pectoral position or vice-versa is mandatory to allow for the polyurethane to grow into virgin tissue.

These implants come in a wide range of shapes and sizes (table 1, figures 1 and 2),



Figure 1 : 4 anatomical shapes, clockwise from upper left : Anatomic, Short Low Profile, Short Moderate Profile, Short High Profile



Figure 2 : inferior view of the 3 projection sizes of the Short Profile implants

just as our patients do! So we are frequently using anatomically shaped implants to try to achieve a result as natural result as possible. The great frustration when using other than round implants, is that one has to be sure that the implant forever stays in the position and orientation that we have put it in. Not one implant surface other than the MPS could deliver us such guarantee.

These implants do not move at all from the position where it was inserted. This is even true to a degree that one cannot rely on the usual “settling” of the implant in the weeks following insertion.

This brings us to the first relative disadvantage of the MPS implants: there is very little or no margin for error in positioning of the implant. We have had a few patients early in our series presenting with high riding position of the implant. Experience has learned that one has to position the implant 1-1,5 cm *lower* than what would be planned in a traditional smooth or textured silicone or inflatable implant.

Palpable folds are another trap early on the learning curve. To prevent folds, it is recommended to make a pocket which is wide enough for the implant to sit in comfortably. This is usually wider than what surgeons are used to create for smooth or textured implants.

After insertion, it is essential to check and double-check the implants for smooth contours, especially in the lower and lateral poles. If any fold is left uncorrected, after tissue ingrowth it will be permanent. If a fold does appear in the postoperative course, one should plan to surgically correct it by detaching and redistributing the implant until a smooth surface is obtained. This can perfectly be planned from 2-3 months postoperatively, when the inflammatory phase of wound healing has settled.

MPS implants are said to be very difficult to remove. Nowadays this has become a stubborn myth. This problem, reported in the early days of PU-covered implants arose mainly due to separation of the polyurethane foam from the silicone implant membrane of the older generation implants, in which the polyurethane layer was glued to the implants. This glue appeared to lose its strength over time. In the present generation of MPS implants the polyurethane is inseparably fixed to the silicone membrane by vulcanization. As a consequence removal of a MPS implant of the new generation is very simple, as the polyurethane remains on the implant. The interface between the

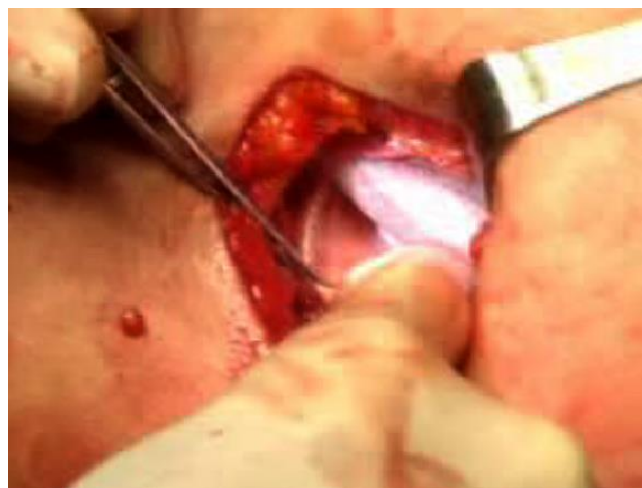

Figure 3 : detaching the implant surface from the surrounding tissue by finger dissection

implant polyurethane surface and the surrounding tissues is easily dissected with the finger (Figure 3). It is more adherent than a textured implant, but still separates easily like opening a Velcro®, and the implant can be detached in toto from its pocket.

A minor disadvantage could be that during the early ingrowth phase the palpation of the implant may be somewhat more solid than another gel implant. This is due to the stiffness of the inflammatory tissue around the polyurethane, and subsides completely after 6-9 months on the average.

Applications

Although initially we reserved the use of the MPS implants for strict indications such as an implant change for correction of capsular contracture, or when an anatomical implant was indicated, the application of these implants are basically exactly the same as for any other breast implant. They can be used in any cosmetic augmentation situation, in a retropectoral as well in a prepectoral position.

We have also been using the MPS implants in secondary breast reconstruction, in combination with, or without latissimus dorsi muscle flap coverage. As with any implant, a poor tissue coverage will eventually result in a degree of palpability or even visibility of the implant, but the incidence of capsular contracture remains very low.

Planning

In the preoperative consultation the planned implant size is determined in concert with the patient, based on the native breast dimensions and with the help of external sizers, which are inserted in a brassiere of the cup size that she is aiming for.

The decision whether to place the implant in a retropectoral or a prepectoral position mainly depends on the thickness of the upper pole breast soft tissue: if the tissue thickness determined by measuring the amount of tissue pinched is less than 3 cm (2 X 1,5 cm) a relative contraindication exists for prepectoral placement. Less than 2 cm is considered as an absolute contraindication. The prepectoral position can be selected if a more direct influence of the implant on the breast shape is desired, for instance with a minor ptosis or in the case of a very short lower pole with a sharp inframammary crease to diminish the risk of a double bubble. To minimize the risk of upper pole visibility the subfascial approach is used.

A retropectoral placement gives a better cranial coverage of the implant, but can increase upper pole fullness due to the added thickness of the pectoral muscle. Some patients dislike the distortion of the breast when contracting the pectoral muscle.

We only use the periareolar and inframammary crease approach. The axillary approach is avoided because of the reported higher incidence of revisions for implant position, and the impossibility of checking the position of an anatomical implant. Also the higher friction surface of an MPS implant makes it virtually impossible to ascertain a smooth placement from the relatively distant axillary entry port.

The inferior hemi circular periareolar incision with transglandular dissection places the scar along an existing line of contrast between the areolar and breast skin. It also provides a superior access to the whole implant pocket including the upper pole. This is particularly valuable for checking the implant for folds in the end of the procedure.

Moreover, it provides a comfortable degree of flexibility in determining the lower limit of dissection and position of the new inframammary crease.

Due to the semicircular shape of the incision a areolar diameter of only 3 cm still allows an incision length of 4,7 cm ($p \times \text{diameter}/2$). With an areola diameter smaller than 3 cm we would advise against this incision.

In the inframammary crease approach the incision is placed exactly at the predicted level of the new inframammary crease, determined according to Tebbetts' algorithm (ref). In most of the cases the inframammary fold is lowered to 4.5-5.5 cm below the areola, according to the size of the implant. An incision length of 4,5 cm is usually sufficient. The incision runs laterally from a line dropped down vertically from the medial areolar border. This approach exposes the border of the Pectoralis Major muscle more easily, but the access to the apex of the pocket is relatively harder. An advantage is that no breast tissue is transected, which avoids contact with the content of any cysts, if present. No microcalcifications are created in the breast. The visualization of the gland through mammography is also better with a retropectoral placement, which is a benefit in cases of strong familial antecedents (maternal) of breast cancer.

Examples of scars of both incisions are shown to the patient, and the choice is left up to her, within the limits of the technical possibilities.

The decision whether to use a round or an anatomical implant is related to the amount of pre-existing breast tissue, the shape of the breast, amount of ptosis and the nipple-jugular distance.



Figure 4 : Anatomical Round Base implant



Figure 5 : Anatomical Horizontal Oval implant

A patient with no or minimal breast tissue forms an absolute indication for an anatomical implant, to avoid unnatural upper pole fullness and a step-off at the upper pole. Further the decision is mainly guided on the nipple-jugular distance and the presence of a degree of breast ptosis (which doesn't require surgical lifting) (Table 2). With a nipple-jugular distance of less than 19 cm we prefer an Anatomical implant with a Horizontal Oval (Table 1, Figure 5), which has a horizontally oval shape. This provides sufficient projection at the nipple, a good expansion of the lower pole and avoids bulging high on the patient's chest. A nipple-jugular distance of more than 19 cm allows the use of a Anatomical Round base shaped implant (Table 1, Figure 4), which is round in frontal view, but has a teardrop shape in profile, thus avoiding exaggerated upper pole fullness.

The degree of ptosis will dictate the projection of the selected implant : more ptosis, higher projection. In the cases where sufficient breast tissue is present round implants can be selected, with a moderate or a high profile according to the patient's breast and thorax shape.

Operative technique

This case selected for step by step description received an MPS implant in a retropectoral position through a periareolar incision.

1. Surgical plan
 - a. Marking
 - b. Infiltration
 - c. Incision and pocket dissection
 - d. Haemostasis
 - e. Insertion of the implant
 - f. Checking implant position
 - g. Pocket and skin closure
 - h. Dressing
2. Operative overview
 - a. Marking (Figure 6)

The marking consists of the planned skin incision, the midline, the existing (red) and the planned (blue) inframammary crease. To determine the inferior position of the implant we adhere mostly to John Tebbetts' algorithm, but lowering the fold an extra 0,5 to 1 cm, it taking into account that MPS implants don't "settle" postoperatively.

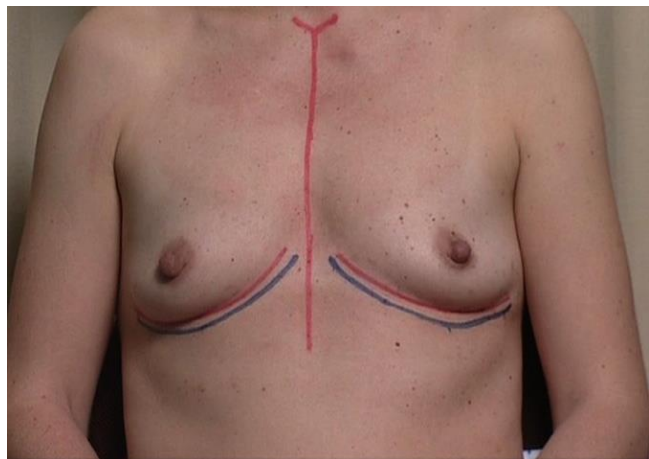


Figure 6

b. Incision

Three pairs of reference points are tattooed before making the periareolar incision. Undulating the incision to a degree makes the scar less conspicuous because less “perfectly” circular, and also gives some extra length to the incision (Figure 7).

The dissection is carried out with the needle tip cautery, transecting the breast tissue perpendicular to the pectoralis surface (Figure 8). Once the pectoralis fascia is encountered, the dissection proceeds laterally towards the lateral Pectoralis Major border.

The Pectoralis border is identified and the undersurface of the Pectoralis muscle is exposed with the cautery, after which the subpectoral dissection is initiated with the dissecting scissors (Figure 9).

A part of the subpectoral dissection can safely be done by blind finger dissection through the areolar subpectoral plane (Figure 10), from medial to laterally to avoid dissecting under the Pectoralis Minor muscle. No attempt is made to disrupt muscular attachments by blunt dissection.

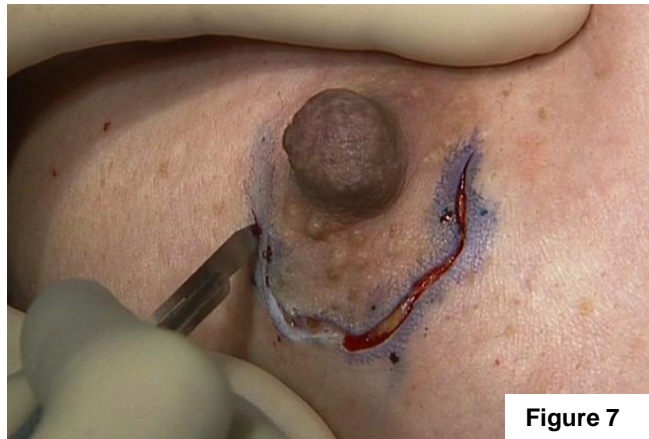


Figure 7

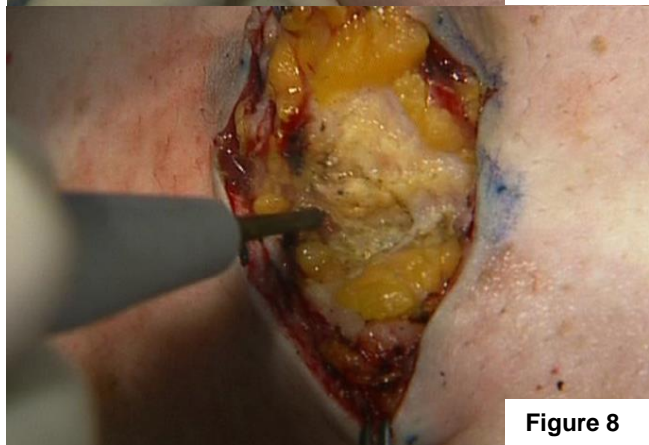

Figure 8

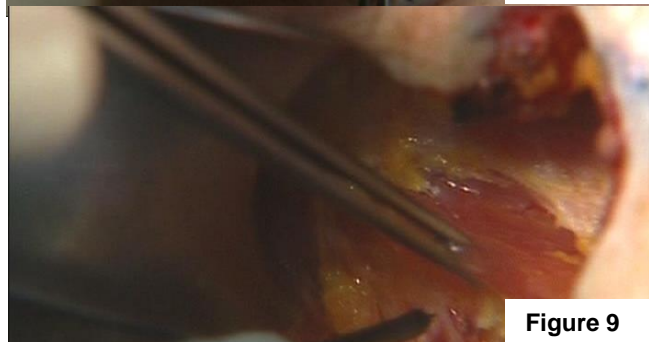

Figure 9

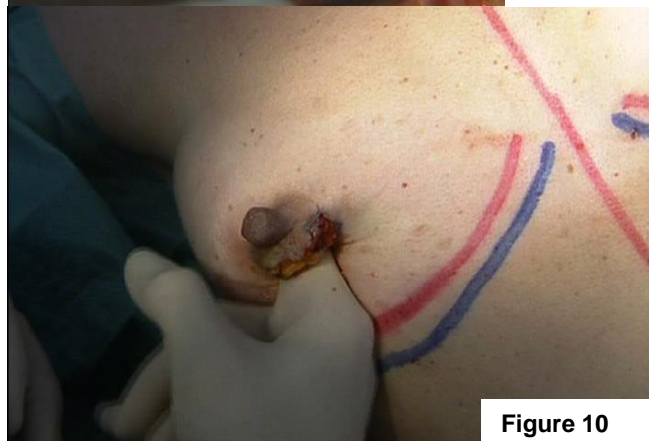

Figure 10

The inferomedial insertion of the Pectoralis Major muscle must be transected from the 6 to the 9 o'clock position on the right, and from the 6 to the 3 o'clock position on the left. This is done under direct vision with the needle tip cautery, to allow a sufficiently medial and inferior placement of the implant (Figure 11). Care is taken to maintain an even depth of transection to avoid unsightly contractile bands postoperatively when the patient contracts the Pectoralis Major muscle.

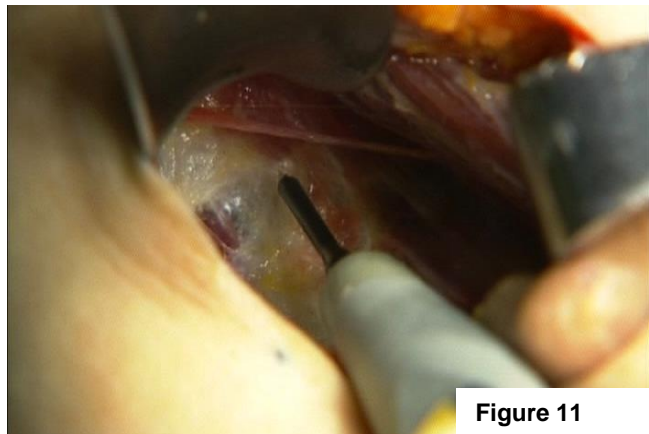


Figure 11

The size of the pocket should be ample, to allow comfortable insertion of the implant. The intraoperative positioning of the implant will be stable thanks to its high friction coefficient. On the other hand, a rather wide pocket will allow for the surgeon to ascertain an even implant surface without any wrinkles or folds.

Before insertion the implant is soaked in a dilute polyvidone iodine solution, and Endosgel® (hydroxyethylcellulose gel,

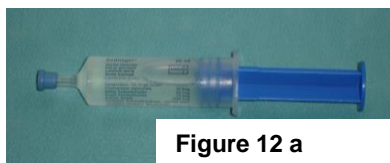


Figure 12 a

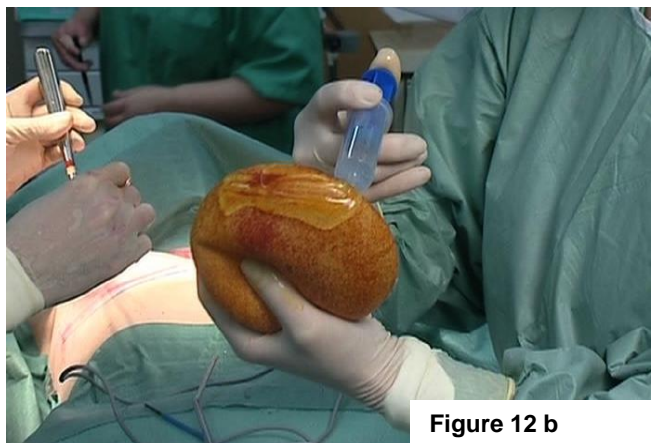

Figure 12 b

Farco-Pharma GMBH Köln, Germany, Figure 12a) is applied on the upper pole of the implant, the retractors and the wound edges for easy insertion through the incision by temporarily reducing the friction coefficient of the implant's surface (Figure 12b). As the gel is water soluble, it is instantly absorbed once the implant is in place.

The implant is inserted while the periareolar incision is held open with two Langenbeck's retractors. A rocking motion allows relatively easy implant insertion, as any inward motion of the implant is "fixed" readily inside due to the high friction coefficient of the MPS surface (Figure 13).

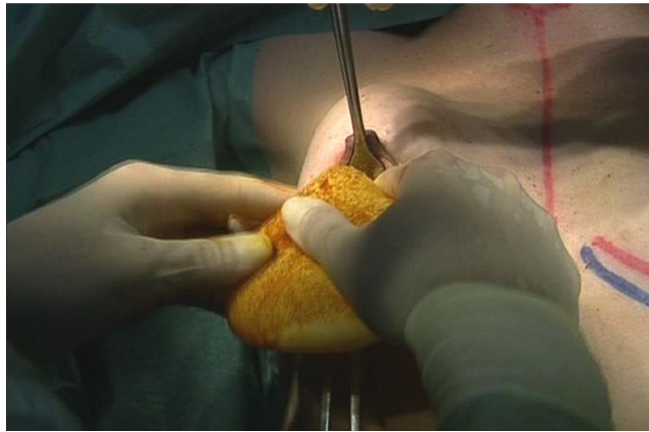


Figure 13

An essential step after implant insertion is the bidigital smoothing out of the implant, making sure that the implant's undersurface is lying flat on the chest wall, and that absolutely no wrinkles or folds are left behind (Figure 14). If a fold persists, it will remain palpable and even visible after implant incorporation, and will necessitate surgical revision.

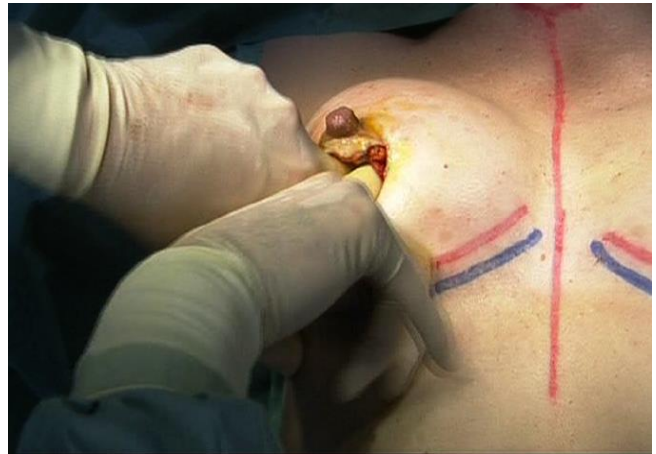

Figure 14

The pocket is closed with interrupted 4-0 Vicryl sutures. Interrupted 4-0 and 5-0 Vicryl sutures close the subcutis, and when a perfect dermal apposition is obtained with the above, only Dermabond skin glue is used to close the skin. Else a 3-0 Monocryl suture is added intradermally.

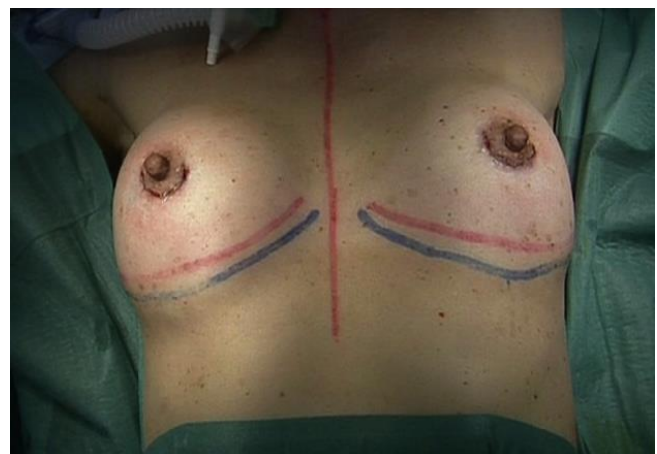

Figure 15 : Final view in recumbant position

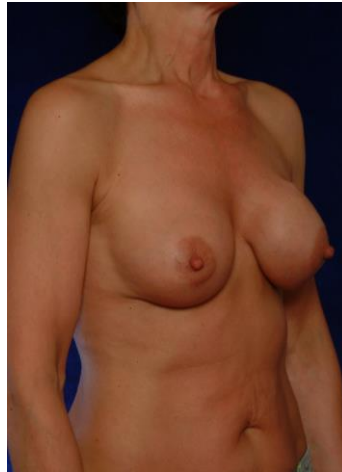Problems and complications

1. Capsular contracture rates

Important information has been obtained by the “Core Study”, conducted by Inamed (now Allergan) and Mentor. These studies were performed to assess the safety and effectiveness of silicone gel filled prostheses as part of the pre market approval application (PMA) to the FDA. The study started in 2000 and was a prospective, FDA authorized and supervised, multiple plastic surgeons study with 10 year follow-up. Augmentation, reconstruction and revision surgeries with round, textured and smooth silicone gel filled implants were performed. The PMA required reporting to the FDA, and the results were to be made public. After 3 year follow-up, Mentor reported a capsular contraction Baker grade III and IV of 8 %. Allergan reported a similar rate of 9% at 4 years. In 2010 the 8 year follow-up results were available and were similar for Allergan as for Mentor: 16.8% of capsular contraction grade III and IV. There were no differences seen between smooth or textured implants, nor between pre- or retropectoral placement of the prostheses. The findings confirm that capsular contraction is a progressive phenomenon, and the longer the patients are followed, the greater the cumulative risk of developing contracture. Handel already suggested this in a PRS article in 2006. Reoperation for any reason at 8 years appeared to be 32.1 %. In this group of reoperated patients, 27 % was for capsular contraction and 14 percent for malposition. This means that 41 % of the reoperations (27 + 14) were for one of the two reasons which are largely preventable by using Polyurethane covered breast implants, as we will see below.

The reported capsular contracture rate (Baker III-IV) in primary breast augmentation with MPS implants lies between 0% and 3,3%. What is even more important than the raw capsular contracture rates, is the long-term probability of remaining contracture-free analyzed with the Kaplan-Meyer method. This reveals that the benefit of MPS implants over smooth or textured implants persists long term, at least 10 years after implantation.

In our experience there was one patient presenting with a clinical unilateral capsular contracture (Baker IV) 5 years after capsulectomy and replacement of a non-MPS textured



cohesive gel implant (Figure 16).

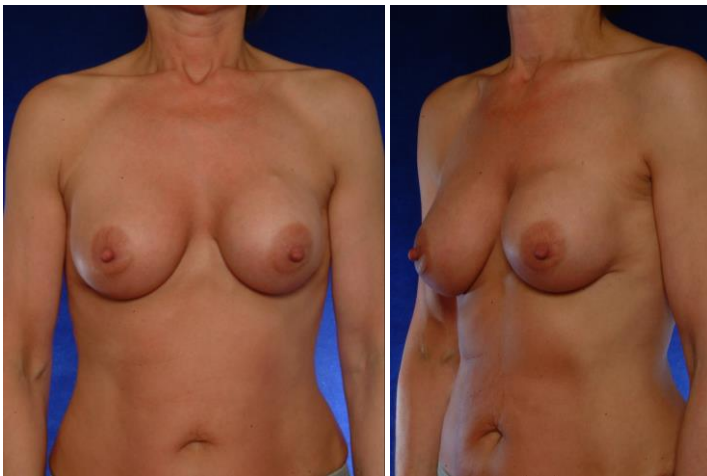


Figure 16 : one case of recurrent left sided capsular contracture after replacement of a non-MPS implant for contracture

Intraoperative findings showed an implant with a “double capsule”, where the implant’s surface was covered with a dense fibrous layer, and was “floating” in a second capsule as a smooth implant. The MPS structure under the fibrous layer was perfectly intact. Most likely this occurred due to a hematoma or seroma shortly postoperatively due to exaggerated mobilization of the implant early postoperatively, preventing ingrowth of the MPS structure. In a second patient upon replacement for larger size, an incidental finding was done of a segmental “double capsule” in the lower pole of one implant, consisting of less than 10% of the implant surface. There were no clinical signs of capsular contracture.

2. Infections

The infection rate reported by Gasperoni is 0,5 % and 1,9% in Handel’s series. In the literature infections rates are found to be similar regardless of implant surface. In our center a single intraoperative dose of cefazolin is given for prophylaxis.

Our series compizes two cases of infection :

The first patient presented five weeks post implantation with a red and tender breast, which she reported to exist already more than ten days. Local drainage and antibiotherapy could not prevent the need for explantation and delayed replacement of the implant.

The second patient presented nine months after implantation with a tender and red area on the lateral edge of her breast. Incision released 50 cc of mainly sanguinous fluid from which *Proteus Mirabilis* was cultured. Local rinsing and antibiotherapy is still ongoing.

3. Palpability

During the early ingrowth phase of the implant a higher palpability may be reported by the patients, when comparing to non-MPS implants. This is due to the foreign-body reaction with neovascularization around the polyurethane surface. This usually subsides in 6 to 9 months after implantation.

The implants were virtually impalpable upon the one-year follow-up visit in more than 95% of the patients.

Obviously very thin patients will always be able to “detect” the implant to some degree in the infero-lateral segment where it is only covered by skin and, in these cases, very little adipose tissue.

In our series 6 patients required a revision for abnormal palpability or folds in the implant. Two of these appeared to have a curling up of the upper pole of the (anatomical) implant, which was due to the high friction coefficient of the implant preventing “settling down” of the prosthesis after insertion. Careful checking whether the implant is lying flat on the thorax in the end of the procedure is mandatory. The four others presented with a sharp fold in the lower pole, probably due to a too narrow pocket. Simple revision solved all six problems.

4. Rippling and wrinkling

Undesirable rippling is a very rare phenomenon with these implants. The low rate of excessive waviness has been reported (Handel) and it is certainly lower than with textured implants. The reported incidence is 6,7%, with a higher likelihood in reconstructive implantations.

We had one patient aged 66 with clinical rippling laterally. The lack of subcutaneous fat tissue together with dermal atrophy due to extensive sun damage probably caused this incidental phenomenon.

5. Poly rash

In the literature almost all authors with experience with polyurethane-covered implants report an incidence of 1-6% of a mild skin rash on the breast surface. When this rash occurs, it arises within 1-3 weeks of the implantation, always is mild, and spontaneously subsides within 2-4 weeks. We have made the same findings early in our series, with an incidence of 2% of a mild skin rash. According to the Polytech Silimed company, which now is the only manufacturer of MPS implants, the rash should have been caused by residus of ETO (Ethylene Oxyde) which was used until then for sterilization. The sterilization process was changed, and since then we have seen no more patients complaining of a skin rash.

Outcomes data

Since January 2001, 1139 micropolyurethane covered silicone gel implants were used in 571 patients by the two authors. 680 of these were anatomical (round teardrop or short profile) implants, 458 round, of which the majority moderate profile. 592 implants were placed prepectoral, and 550 in a partial retropectoral position.

The periareolar incision was used in 498 cases, an inframammary incisions in 640.

There has been one case of unilateral capsular contracture ((0,2%) after replacement of a non-MPS implant for capsular contracture. So far, there have been no capsular contractures in any of our primary MPS-implanted patients. All breast augmentation patients are followed-up yearly, with a drop-out rate of 19 %.

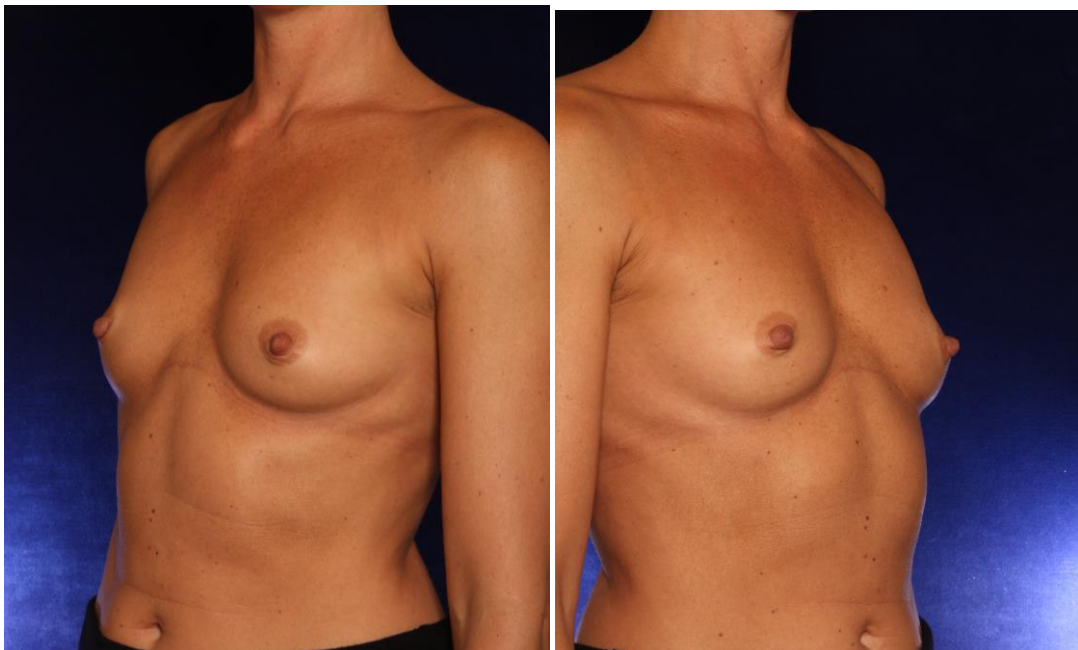
Early in the series there have been 6 revisions for shape correction (palpable fold) and 2 for correction of high riding implants position.

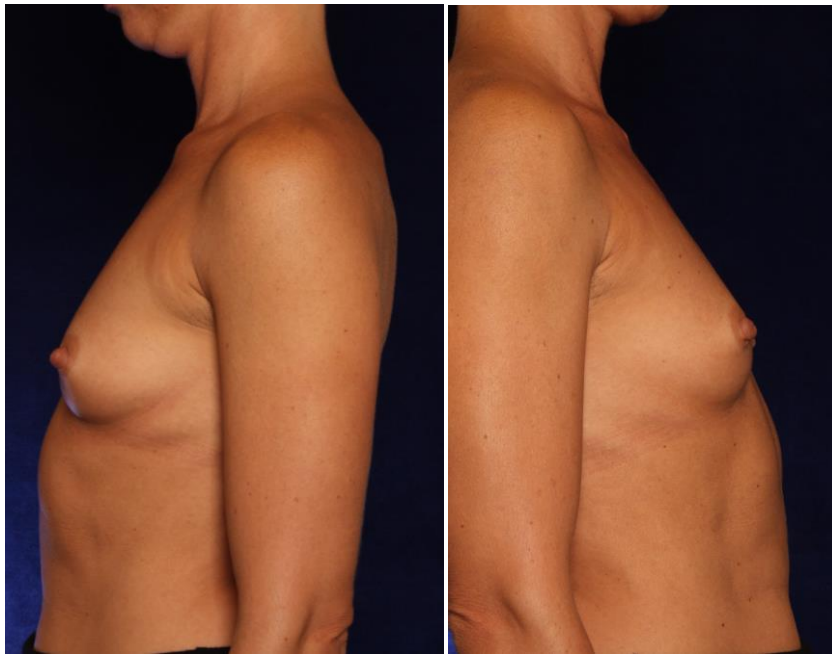
A specific phenomenon is the slightly firmer palpation of the breast during 6-9 months, which is due to the inflammatory reaction around the implant during the early ingrowth phase. Patients should be warned about this and reassured that this is temporary. At the one-year follow-up implant softness is very good and the palpability very low. Overall a very high patient satisfaction was noted both with the aesthetic result as with the functional outcome.

CASE 1

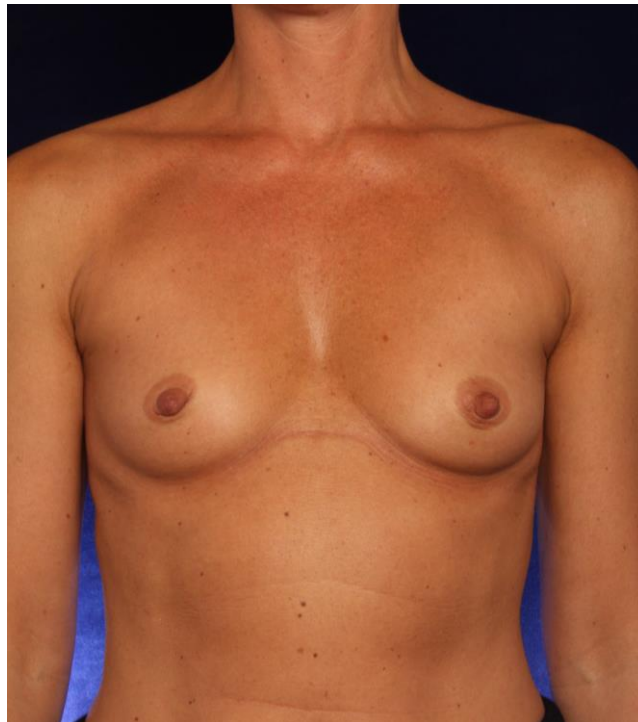

Figure 17





This 30-year old lady requested a breast augmentation after delivering 2 children and loss of breast volume. Preoperatively she had an A-cup, and wanted to obtain a B-cup. She is 172 cm tall and weighs 52 kg, and has a relatively wide thorax and shoulders.

Breast measurements were :

- nipple-jugular distance : 1 8 cm bilaterally
- areola diameter : 3,5 cm bilaterally
- areola-IMF distance : 4 cm bilaterally
- breast width : 13 cm bilaterally
- upper pole pinch test : 2 cm bilaterally

She also specifically requested a narrow cleavage. For this reason, despite the relative contraindication, we decided to place the implants in a prepectoral position. In concert with the patient an implant size of 255 cc was chosen. A Silimed MPS anatomical, horizontal oval, moderate projection implant was selected because of the short nipple-jugular distance and limited own breast tissue. An inframammary incision was selected because of the limited areola diameter. The new inframammary fold was lowered to 5,5 cm below the areola to center the implant over the nipple.

Before implant insertion the midline is marked with methylene blue (Figure 18), so that we have full control over the implant's position and orientation.

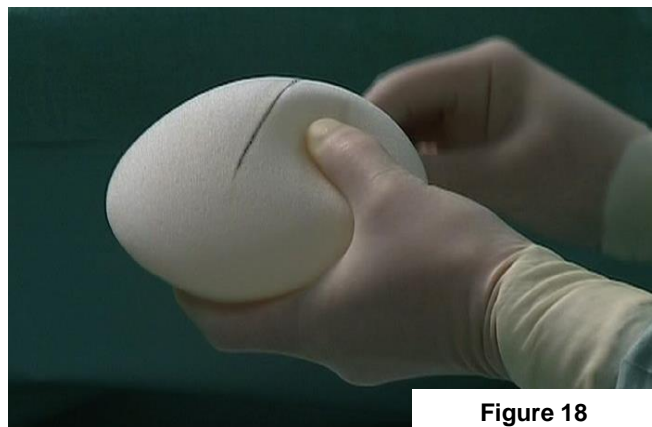
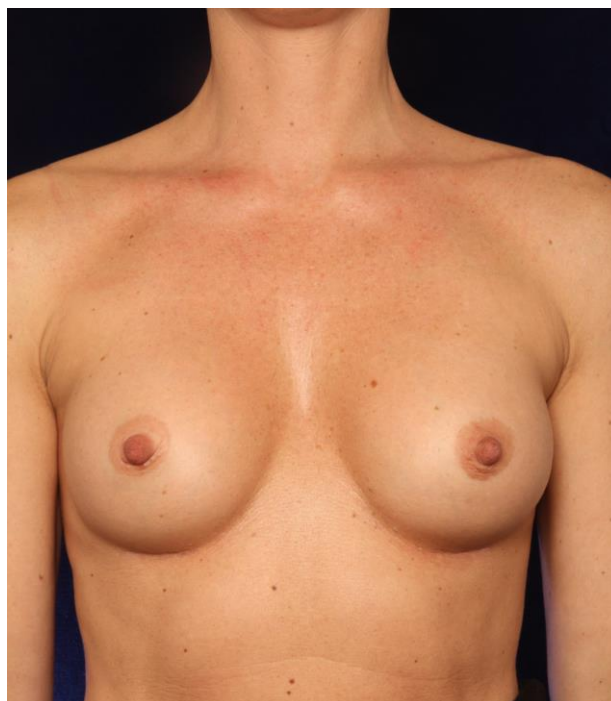


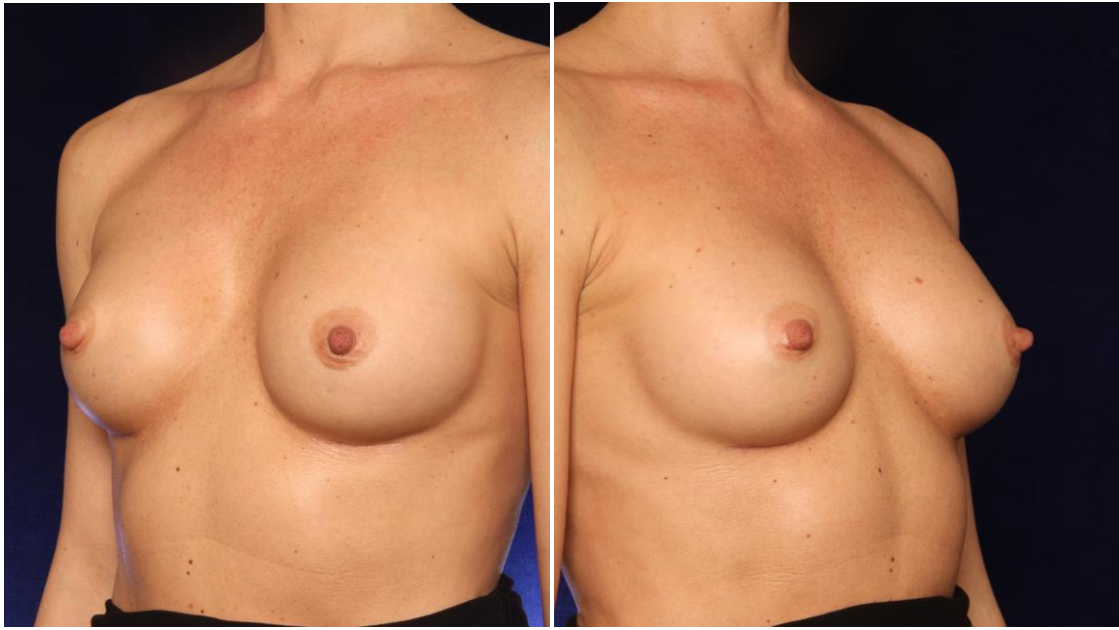
Figure 18

Note that the implant is inserted very low in the pocket (Figure 19). This is important as one cannot count on the implant “settling” postoperatively. It will not descent anymore after the wound is closed. The new inframammary crease is marked in blue, and the medial limit of the skin incision is dropped down from the medial edge of the areola (dashed blue line).

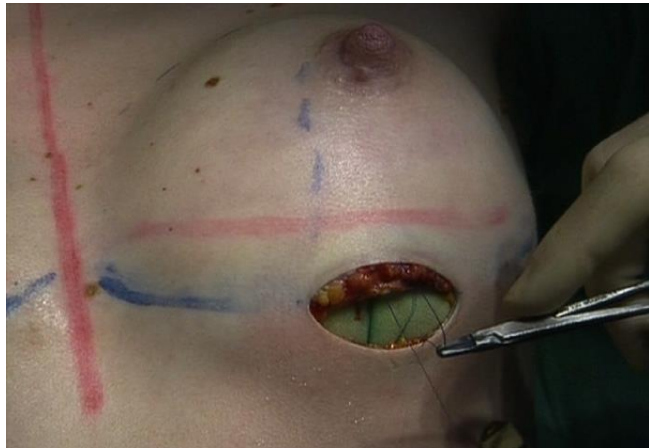

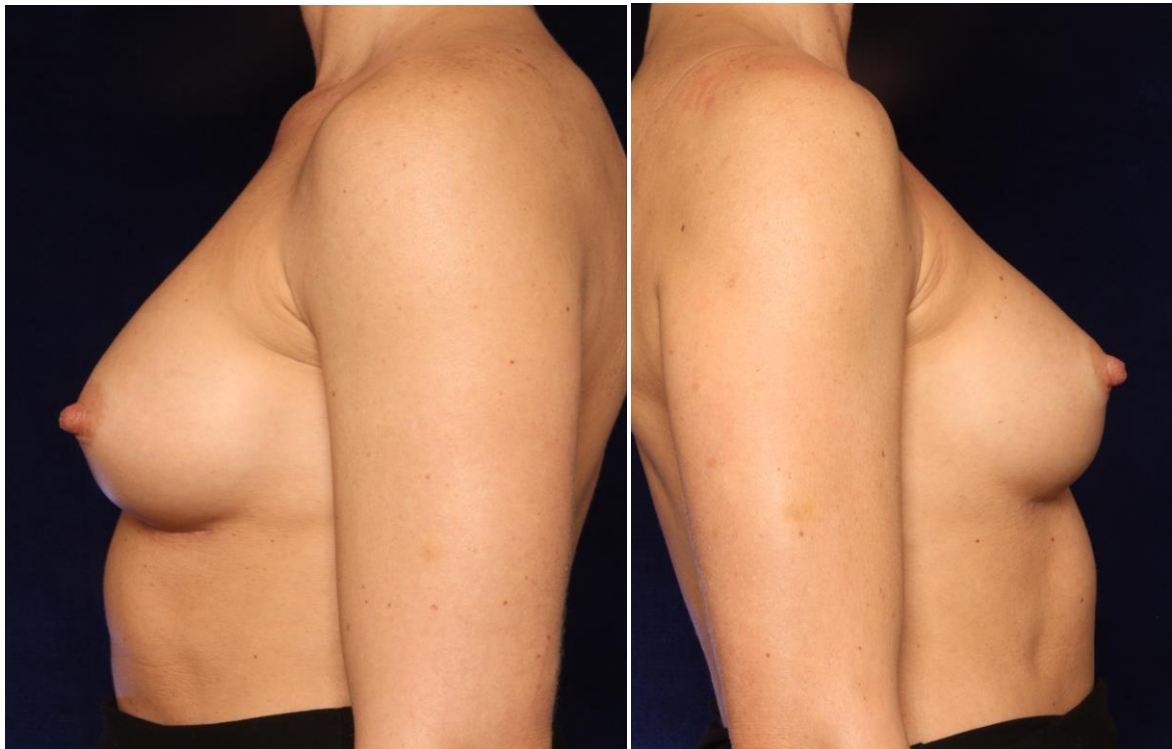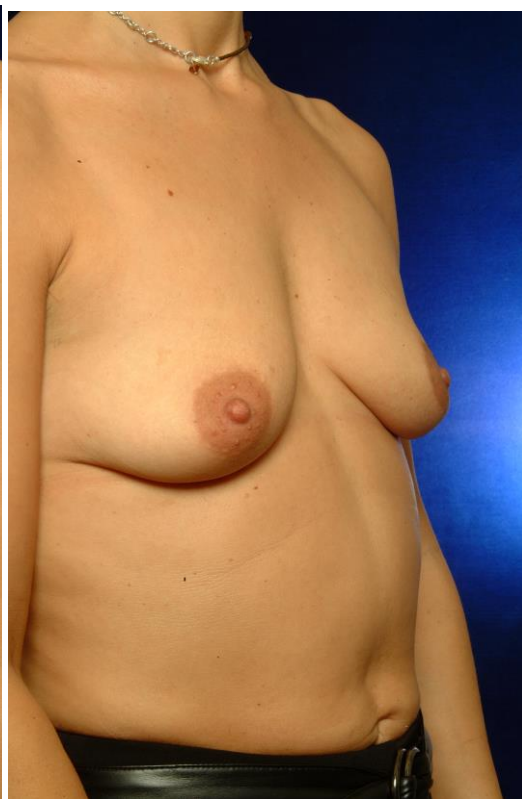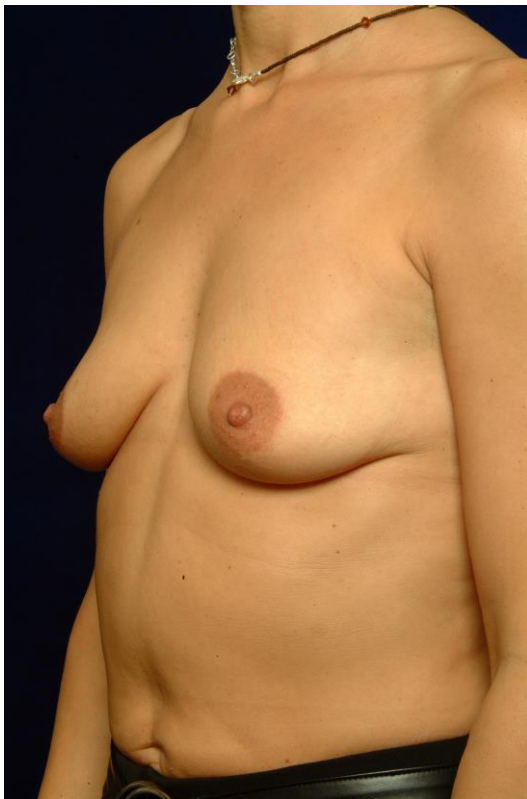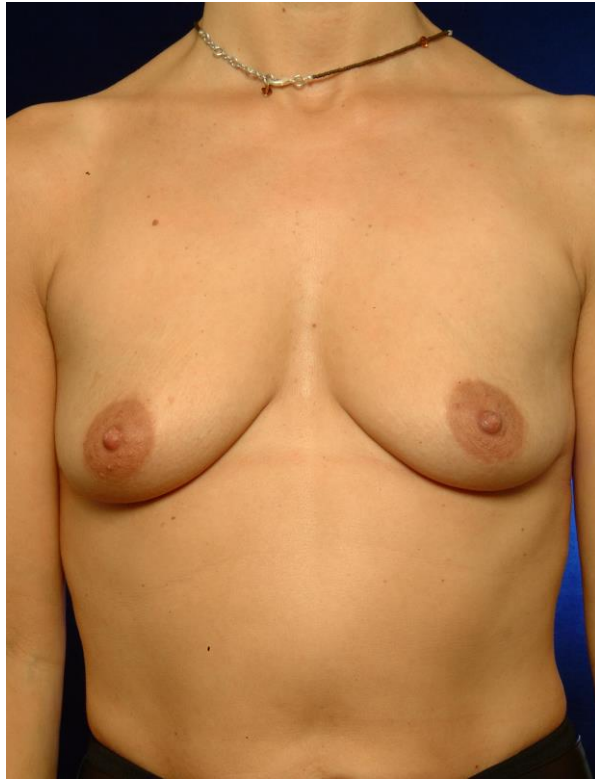
Figure 19

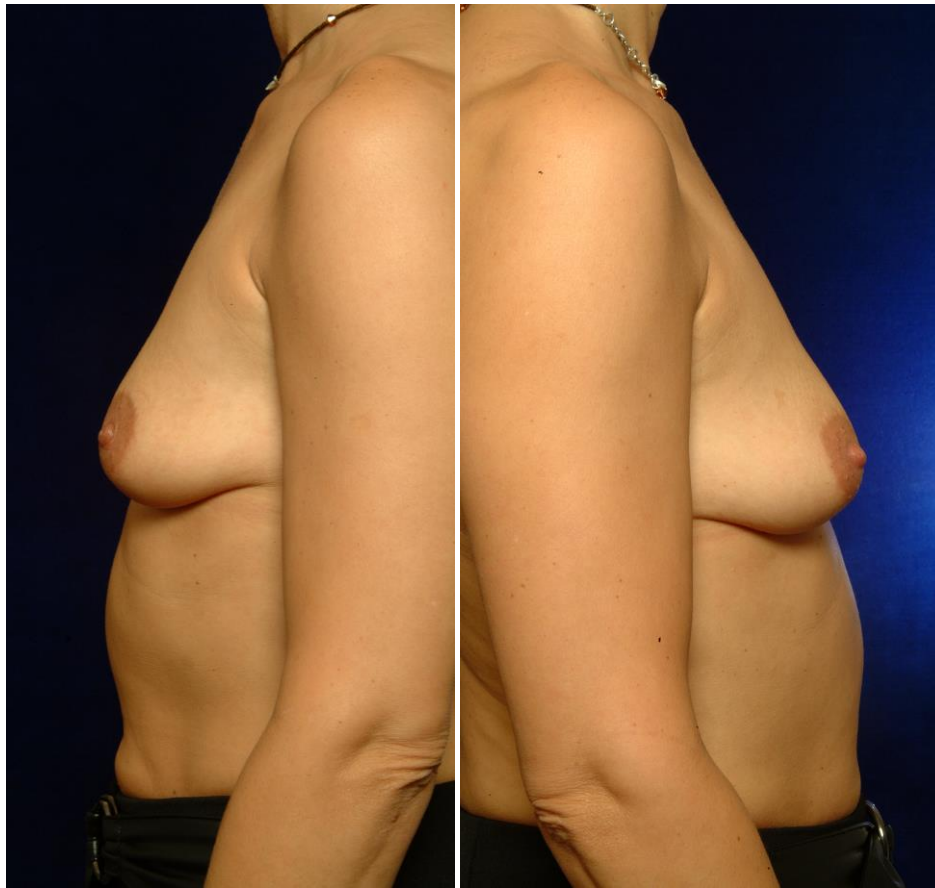




The one-year postoperative situation shows an adequate augmentation for the patient's habitus, with a well-defined cleavage as requested. There is no exaggerated upper pole bulging, the implant is well-centered over the nipple and there is a good expansion of the lower pole. There is no visual neither palpable waviness or rippling, and the implants are impalpable.

Case 2



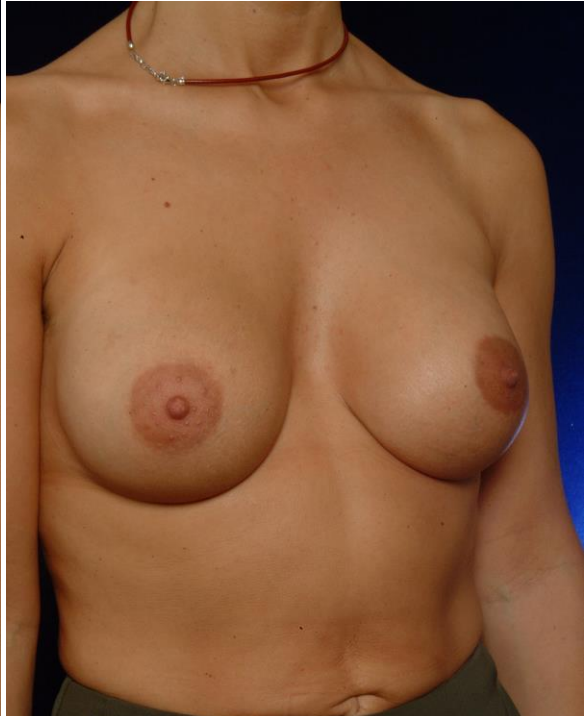
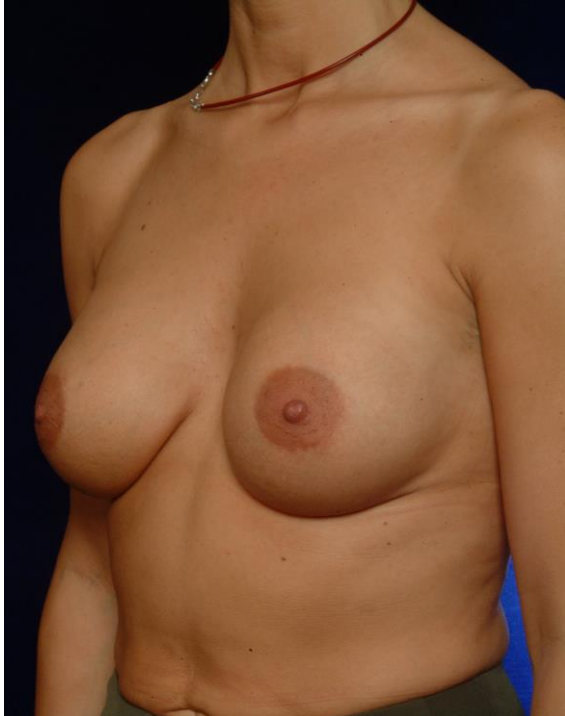
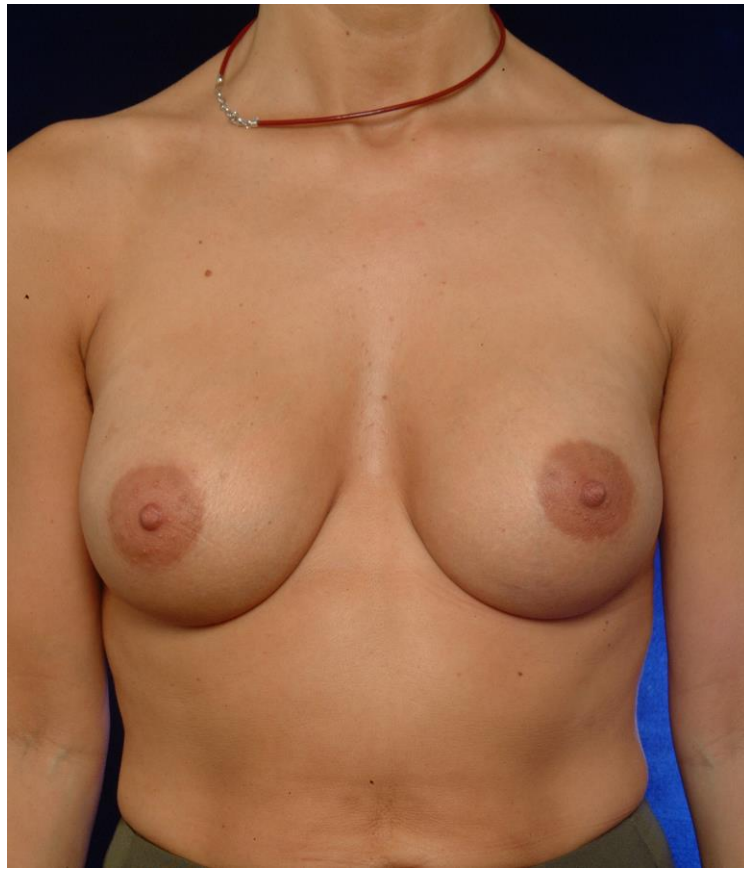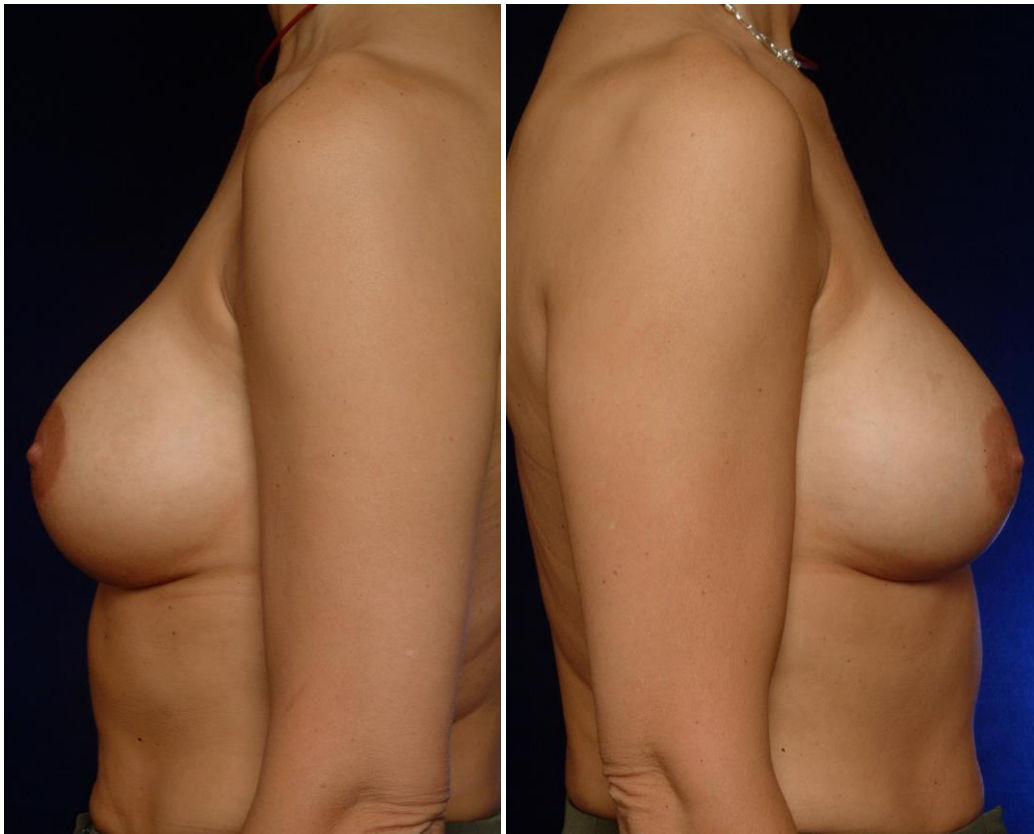This 39-year old lady has an B-cup with a mild glandular ptosis and loss of upper pole fullness. She wants an augmentation to a C-cup. She is 165 cm tall and weighs 54 kg. She has an average thorax width, but relatively wide shoulders.

Breast measurements were :

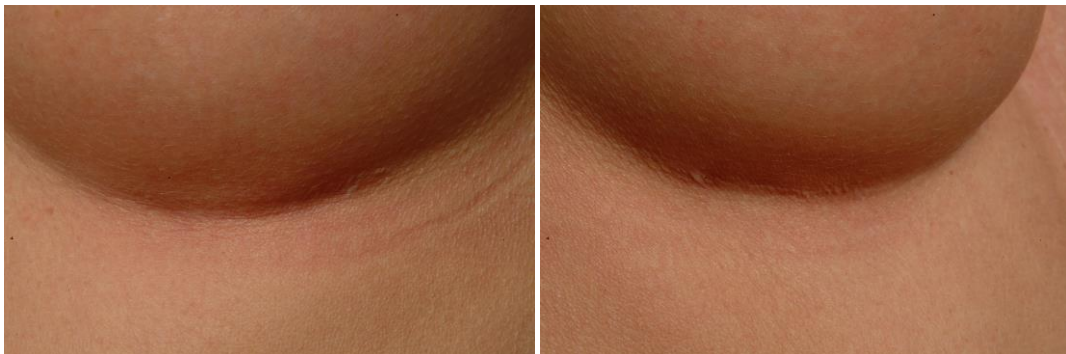- nipple-jugular distance : 22 cm bilaterally
- areola diameter 3 cm bilaterally
- areola-IMF distance 4,5 cm bilaterally
- breast width : 12 cm bilaterally
- upper pole pinch test : 2,5 cm bilaterally

In concert with the patient an implant size of 215 cc was chosen. A Polytech Silimed MPS anatomical round base high projection implant was selected, which has a round base, and a teardrop shape in profile. This will provide maximal projection at the nipple, while still ensuring replenishment of the upper pole. An inframammary incision was selected because of the limited areola diameter. The new inframammary fold was lowered to 5 cm below the areola to center the implant over the nipple.





The one-year postoperative situation shows an adequate augmentation for the patient's habitus, a correction of the mild glandular ptosis visible by the blunted inframammary fold, and a straight upper pole with restored volume.



The detail pictures of the inframammary fold show a very inconspicuous scar exactly at the fold.

References

- Ashley FL. A new type of breast prosthesis. Preliminary report. *Plast Recon Surg* 1970; 45:421-24
- Ashley FL. Further studies on the natural-Y breast prosthesis. *Plast Recon Surg* 1972; 49:414-19
- Brand KG. Infection of mammary prostheses : a survey and the question of prevention. *Ann Plast Surg*. 1993;30:289-95
- Cardy H. Carcinogenicity and Chronic Toxicity of 2,4-Toluenediamine in F344 Rats. *J Natl Cancer Inst* 1979; 62:1107-16
- Chan SD, Birdsell DC and Gradeen CY. Detection of toluene diamines in a patient with polyurethane-covered breast implants. *Clin Chem* 1991; 37:2143
- Cohney BC and Mitchell S. An improved method of removing polyurethane foam-covered gel prostheses. *Aesth Plast Surg* 1997;21:191-92
- Fisher JC. What will historians say? *Plast Reconstr Surg* 1992; 90:118-9
- Gasperoni C, Salgarello M, Gargani G. Polyurethane-covered mammary implants : a 12-year experience. *Ann Plast Surg* 1992 29;303-8
- Handel N, Silverstein MJ et al. Comparative Experience with Smooth and Polyurethane Breast Implants Using the Kaplan-Meier Method of Survival Analysis. *Plast Recon Surg* 1990; 88:475-81
- Handel N, Jensen A et al. The Fate of Breast Implants : a Critical Analysis of Complications and Outcomes. *Plast Recon Surg* 1995; 96:1521-33
- Handel N. Long-term safety and efficacy of polyurethane foam-covered implants. *Aesth Surg J* 2006; 26:265-274
- Hester TR, Ford NF, Gale PJ, et al. Measurement of 2,4 Toluenediamine in urine and serum samples from women with Mème or Replicon breast implants. *Plast Recon Surg* 1997; 100:1291-98
- Hester TR, Tebbetts JB, Maxwell GP. The polyurethane-covered mammary prosthesis : facts and fiction (II). *Clin Plast Surg* 2001; 28:579-86
- Sepai O, Henschler D, Czech S, et al. Exposure to toluenediamines from polyurethane-covered breast implants. *Toxicol Lett* 1995; 77:371
- Tebbetts JB. Dimensional Augmentation Mammoplasty Using the BioDimensional System. Santa Barbara, Calif. : McGhan Medical Corporation, 1994; 1-90
- Vasquez GA. A Ten-Year Experience using Polyurethane-covered Breast Implants. *Aesth. Plast. Surg.* 1999; 23:189-96
- Vazquez and Pellon, Polyurethane-Coated Silicone Gel Breast Implants Used for 18 years. *Aesthetic Plastic Surgery* 2007; 31:330-336

Table

